INFLAMMATORY DISEASES OF THE BONE

LAB.5

ORAL PATHOLOGY

DR.NOOR

Compact bone

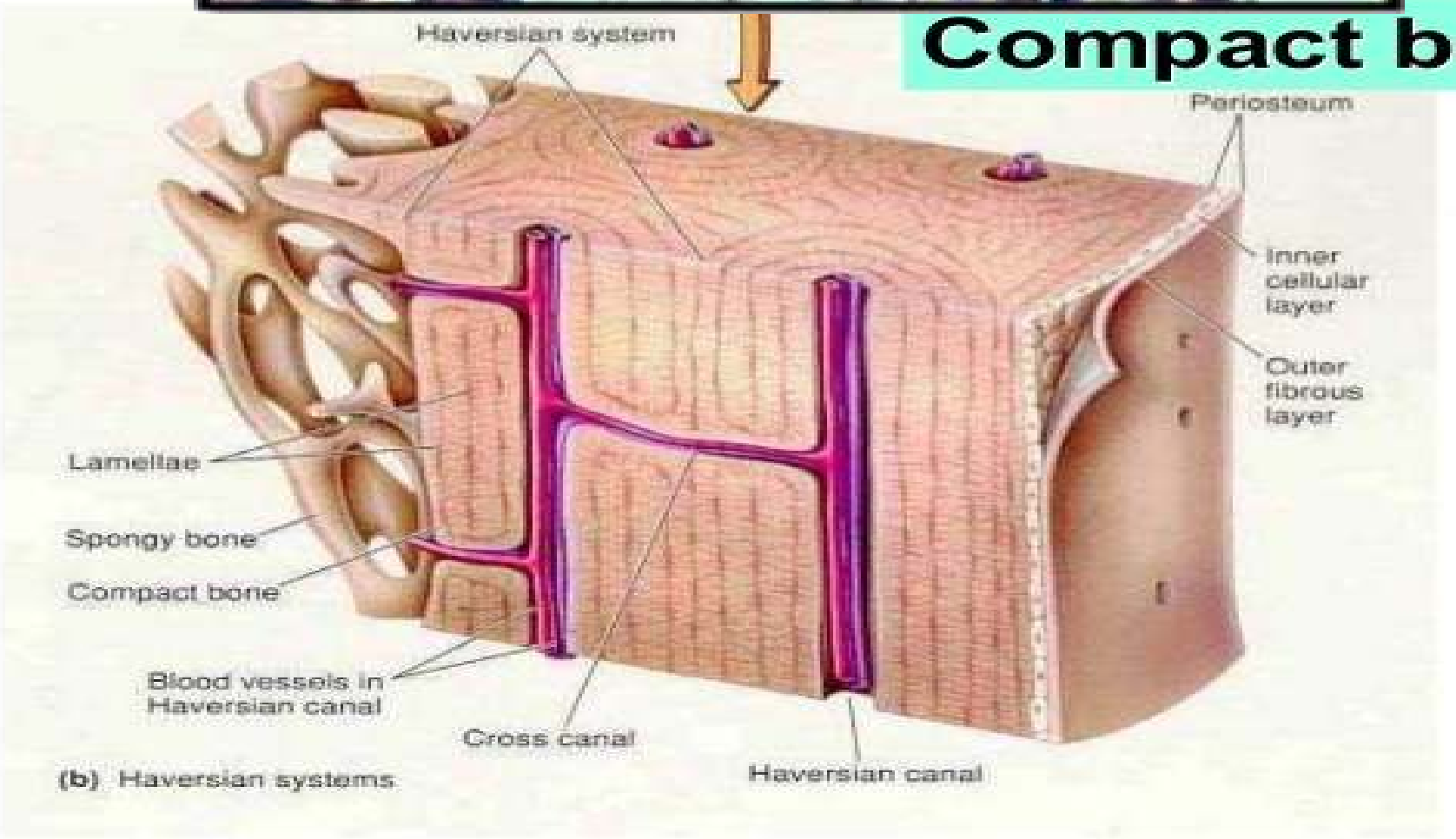

1-Osteitis: - A localized inflammation of bone with no progression through the marrow spaces. Particularly that associated with infected sockets following removal of teeth, **(Dry socket)**

2-Osteomyelitis: - Extensive inflammation of the interior of the bone involving, and typically spreading through the marrow spaces.

3-Periostitis: - Inflammation of the periosteal spaces of the bone and may not be associated with osteomyelitis.

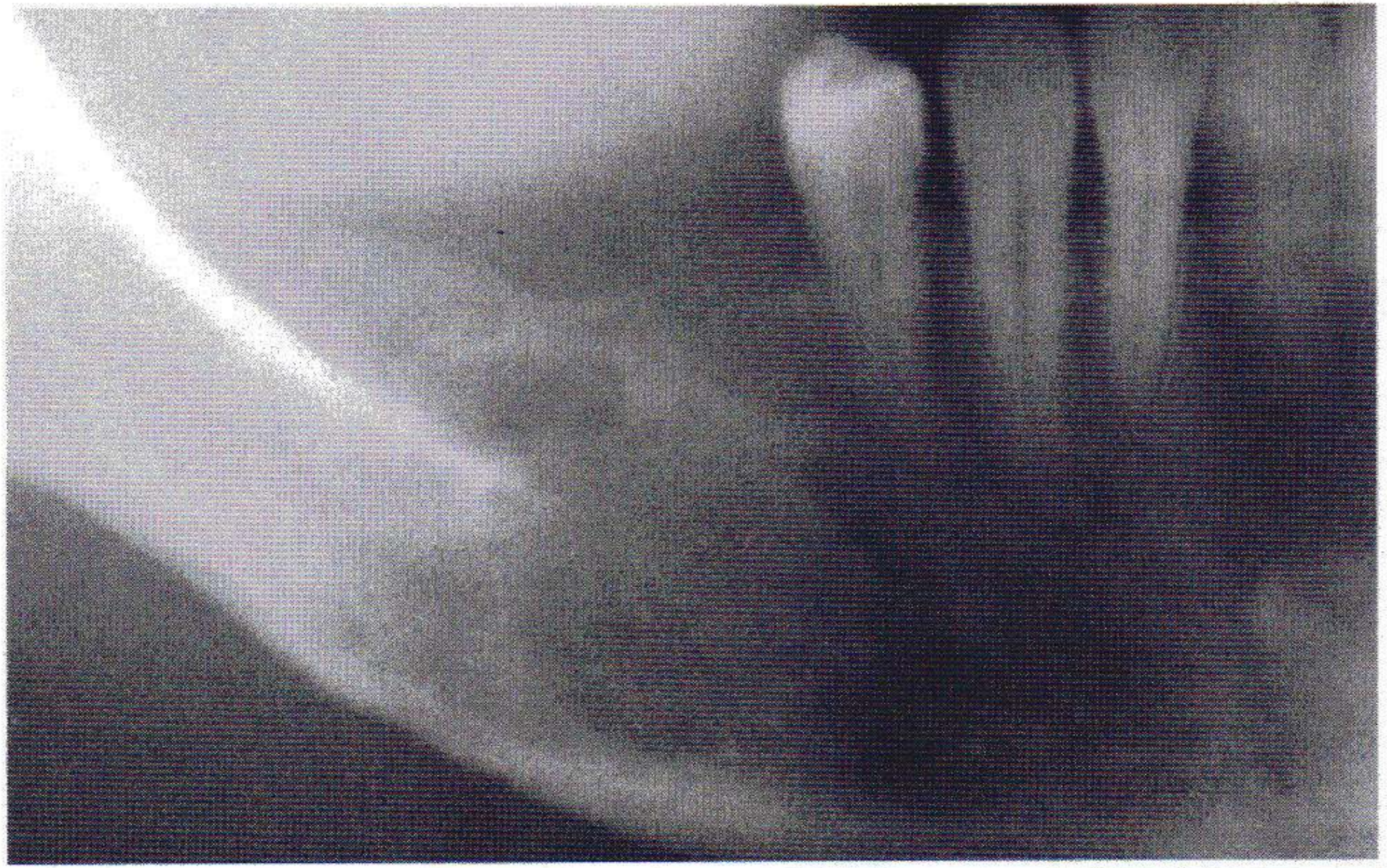

◆ **Acute osteomyelitis.** Ill-defined area of radiolucency of the right body of the mandible.

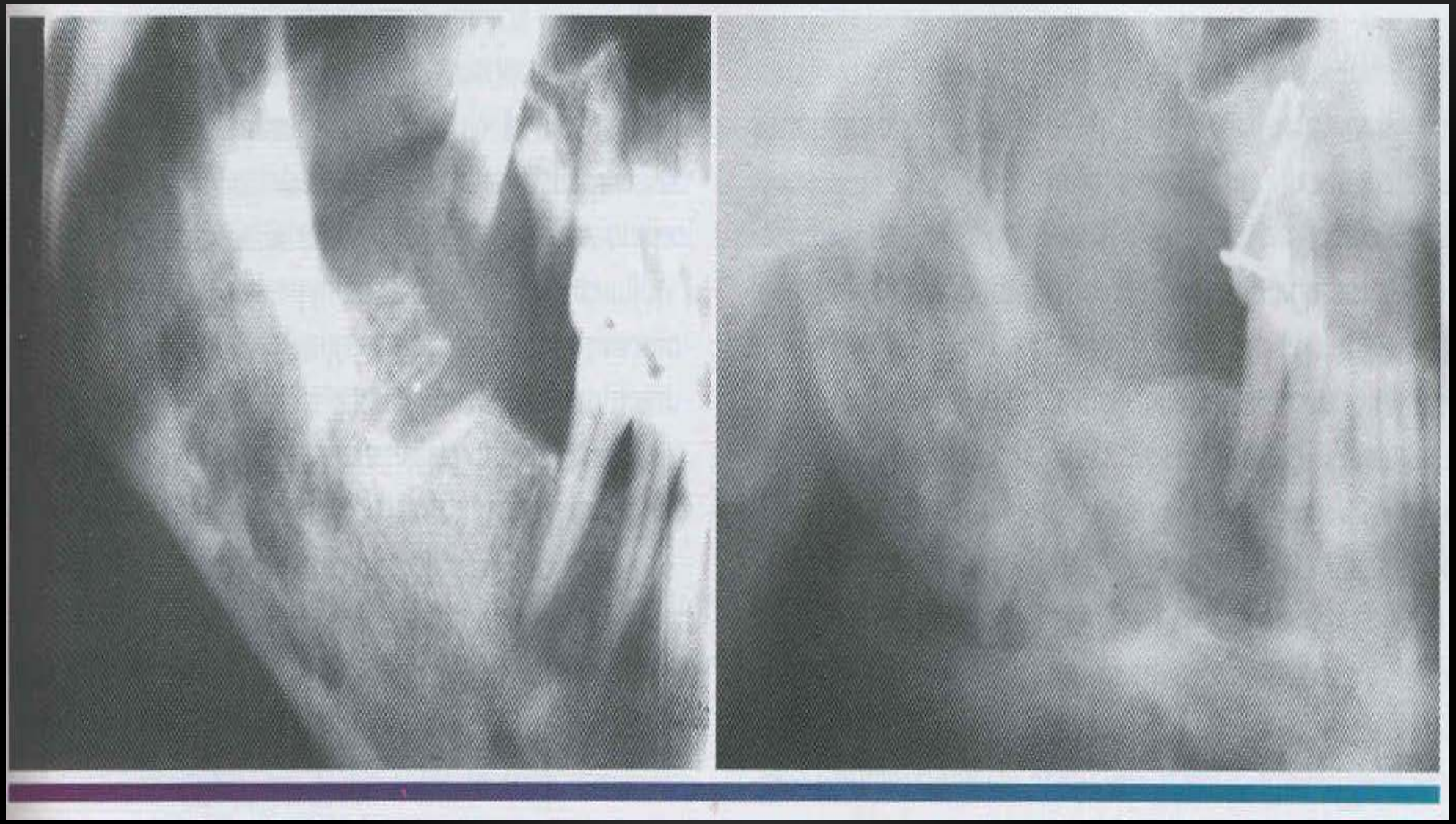

Acute suppurative osteomyelitis

The condition results when an acute inflammatory process spreads through the medullary spaces of the bone and insufficient time has passed for the body to react to the presence of the inflammatory infiltrate .

Chronic suppurative osteomyelitis

- The condition result when the defensive response leads to the production of granulation tissue, which subsequently forms dense scar tissue in an attempt to wall of the infected area.
- The encircled dead space acts as a reservoir for bacteria, and antibiotics are difficult to reach the site. Its difficult to manage unless the problem is treated

Acute suppurative osteomyelitis

Acute osteomyelitis.

- Patients with acute osteomyelitis have signs and symptoms of an **acute** inflammatory process that has typically been less than 1 month in duration, Fever, leukocytosis, lymphadenopathy, significant sensitivity And soft tissue swelling of the affected area may be present.
- The radiographs may be unremarkable or may demonstrate an ill-defined radiolucency.
- **Paresthesia** of the lower lip occur.
- A fragment of necrotic bone that has separated from the adjacent vital bone is termed a Sequestrum.

Acute osteomyelitis with sequestrum. Radiolucency of the right body of the mandible with central radiopaque mass of necrotic bone.

CHRONIC OSTEOMYELITIS.

- The process may arise primarily without a previous acute episode. There may be swelling, pain, sinus formation. purulent discharge, sequestrum formation, tooth loss, or pathologic fracture.
- Patients may experience acute exacerbation or periods of decreased pain associated with chronic smoldering progression.
- Radiographs reveal a patchy. ragged and ill-def ned radiolucency that often contains central radiopaque

CHRONIC OSTEOMYELITIS IN RADIATED MANDIBLE.

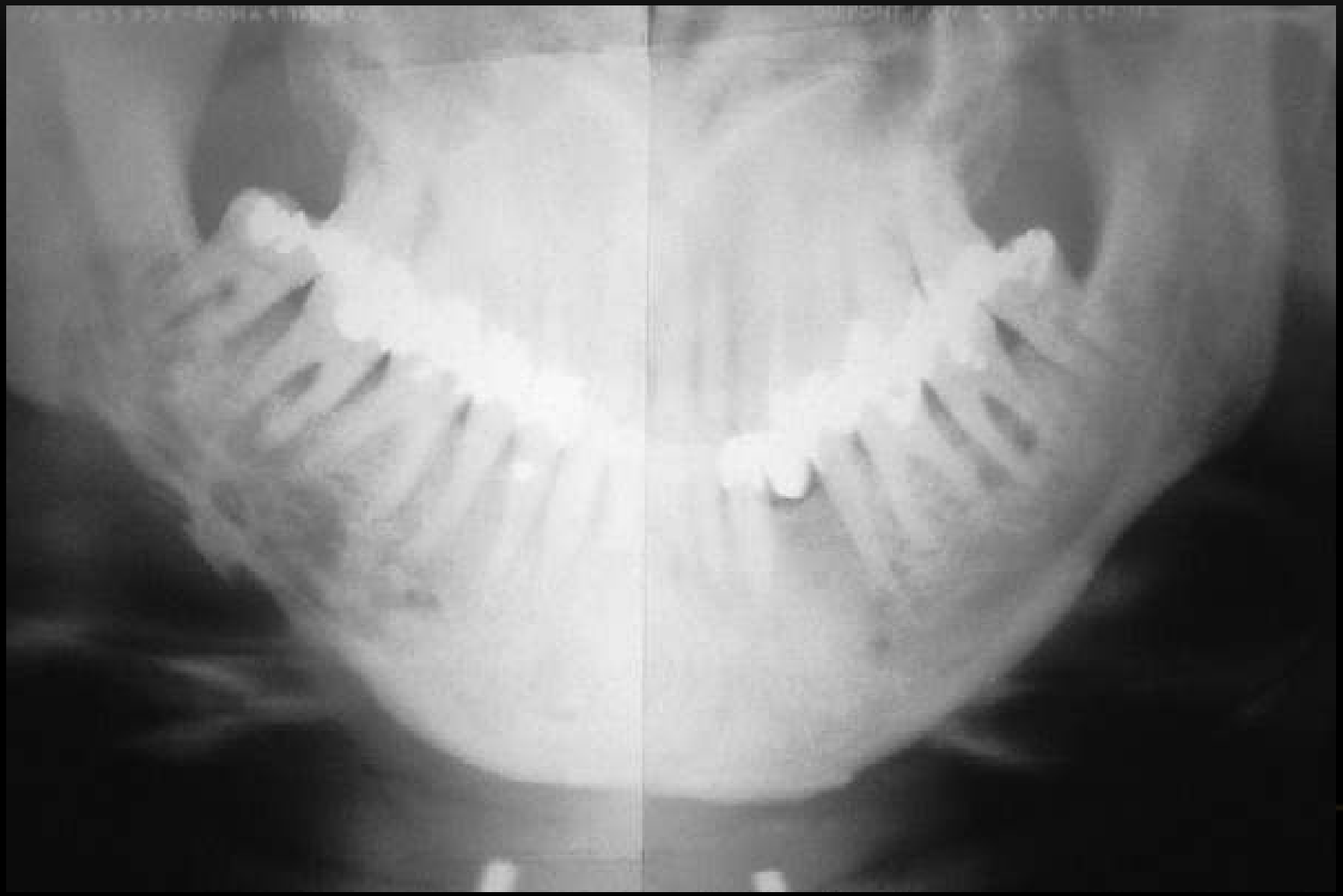

Chronic osteomyelitis of the mandible associated with periodontal disease. Note moth-eaten radiolucent appearance.

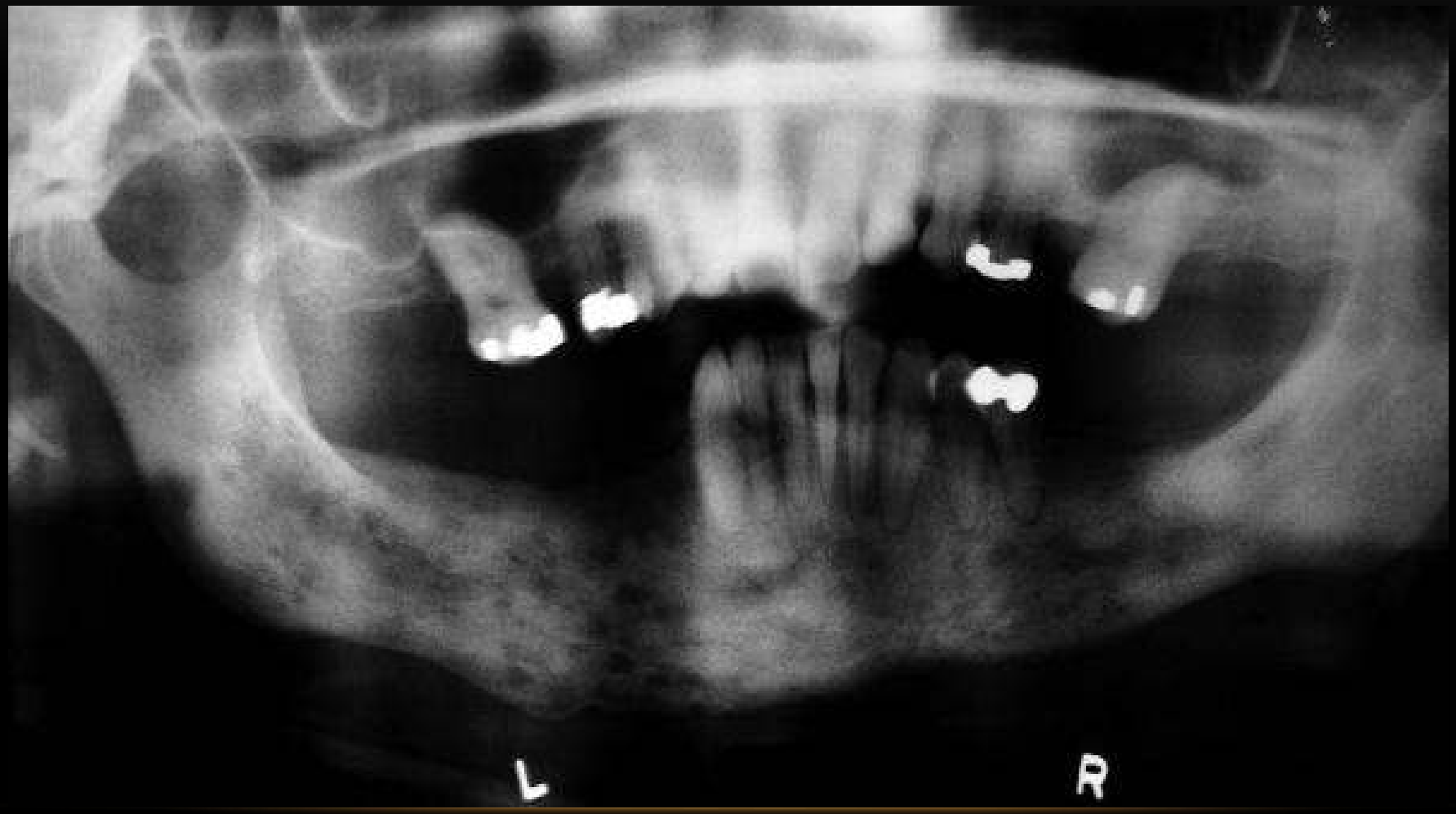

Histopathologic features

- Acute osteomyelitis.
- Generation of biopsy material from patients with acute osteomyelitis is **Not** common because of the predominantly liquid content and lack of a soft-tissue component.
- When submitted. the material consists predominantly of necrotic bone. The bone shows a loss of the osteocytes from their lacunae.
- The periphery of the bone and the haversian canals contain necrotic debris and an acute inflammatory

Acute osteomyelitis. Non vital bone exhibits loss of the osteocytes from the lacunae. Peripheral resorption. Bacterial colonization. And surrounding inf ammatory response also can be seen .

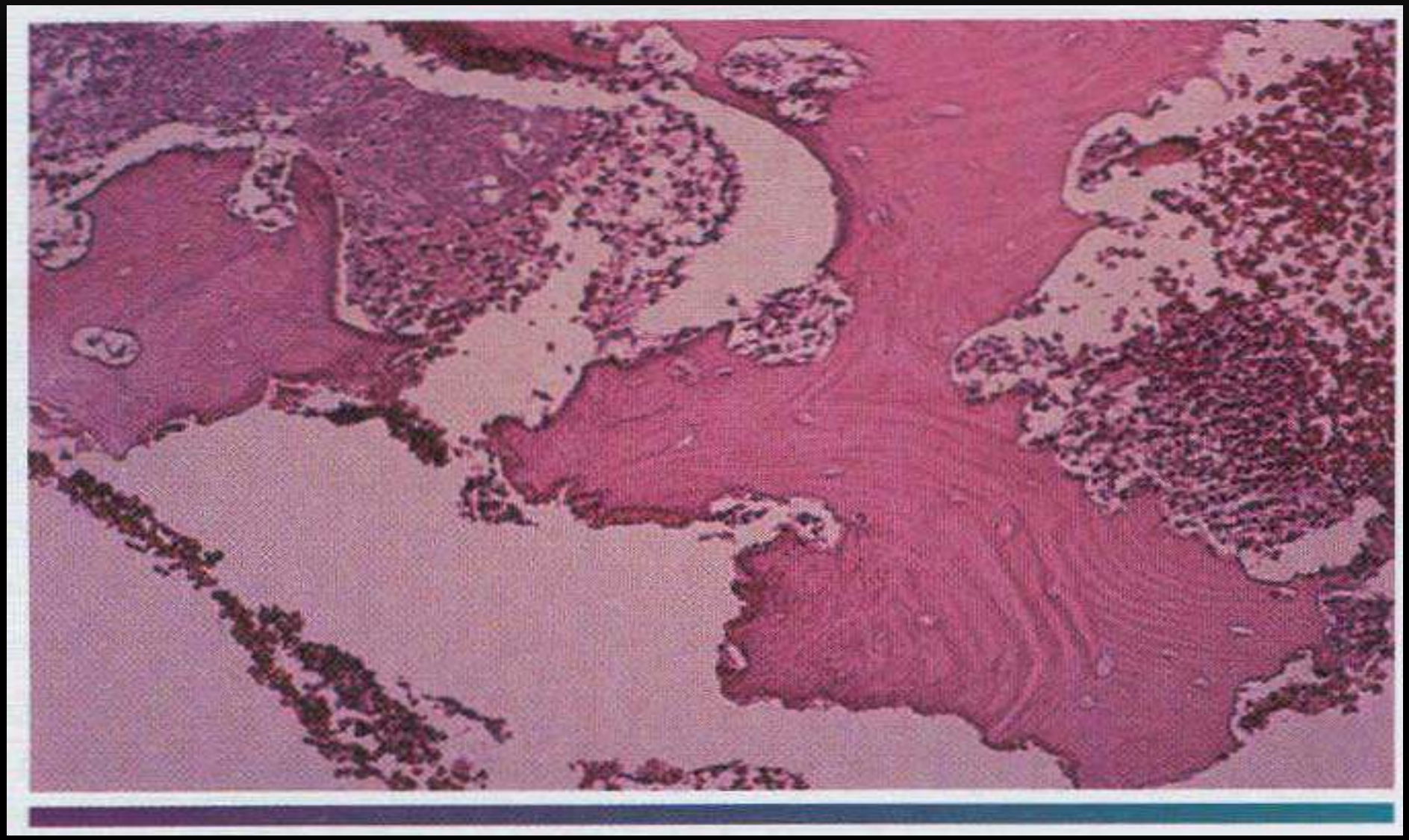

Histopathologic features

Chronic.osteomyelitis

Biopsy material from patients with chronic osteomyelitis demonstrates a significant soft tissue component that consists of chronically or sub acutely inflamed fibrous connective tissue filling the Intertrabecular areas of the bone.

Scattered sequestra and pockets of abscess formation are common.

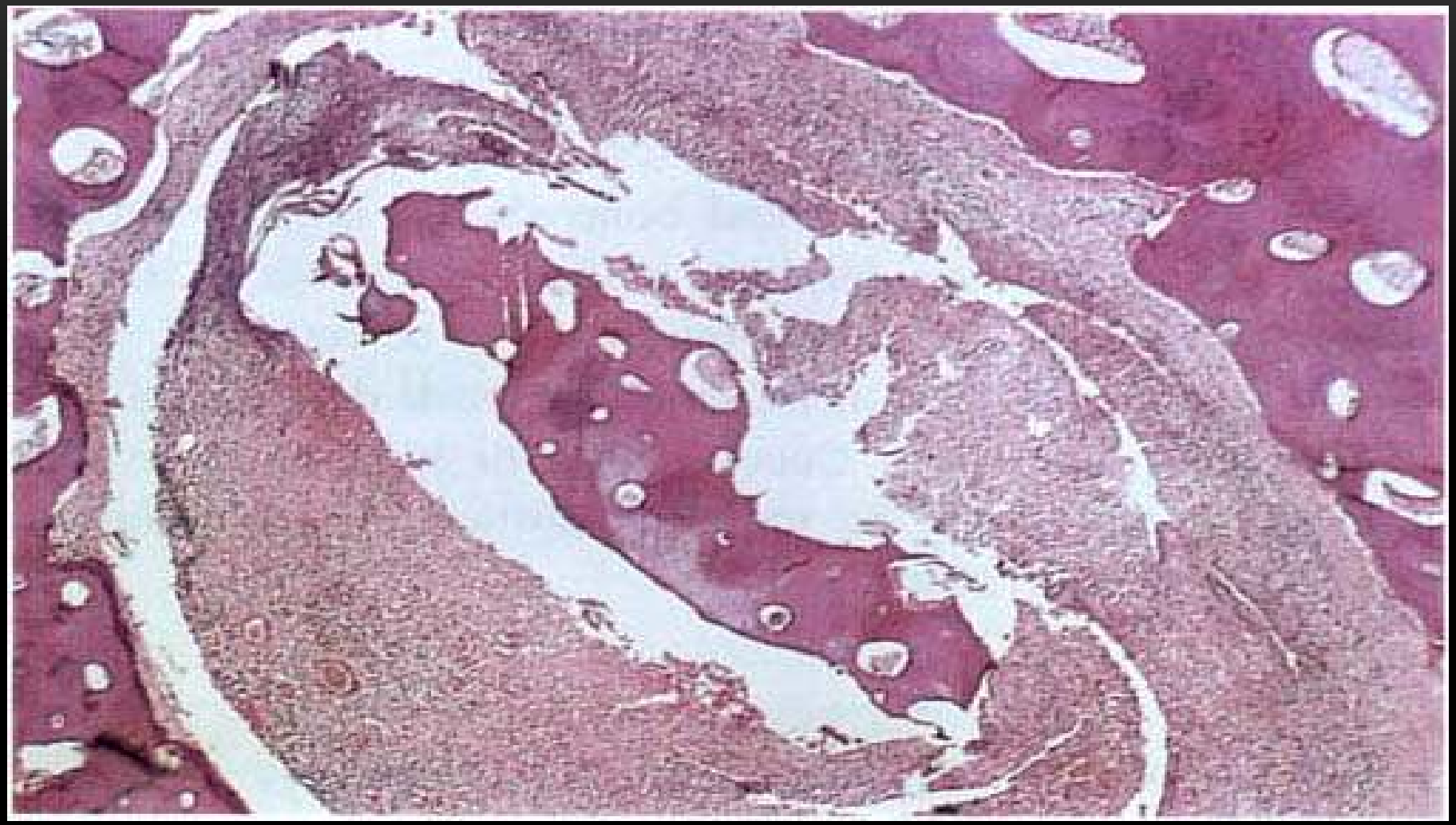

Late-stage chronic osteomyelitis. A sequestrum trapped in a cavity within the bone. It is surrounded by f brous tissue containing an infiltrate of inflammatory cells.

A Sequestrum showing non-vital bone (the osteocyte lacunae are empty), and eroded outline with superficial lacunae produced by osteoclastic resorption, and a dense surface growth of bacteria.

CONDENSING OSTEITIS
Focal sclerosing osteitis

- It is usually seen at the apex of a tooth with long-standing pulpitis. This lesion may occasionally be adjacent to a sound, unrestored tooth, suggesting that other etiologic factors such as malocclusion may be operative.

FOCAL SCLEROSING OSTEITIS.

- Radiographically, one of several patterns may be seen.
- Uniformly opaque
- A peripheral lucency with opaque center
- Opaque periphery with a lucent center
- Confluent or lobulated opaque masses.

HISTOPATHOLOGY

- Microscopically, these lesions are masses of dense sclerotic bone. Connective tissue is scant, as are inflammatory cells.
- Differential Diagnosis
- Differential diagnosis should include periapical cemental dysplasia, osteoma, complex odontoma, cementoblastoma, osteoblastoma, and hypercementosis. In most cases, however, diagnosis can be made with confidence on the **basis of historical and radiographic features.**

diffuse sclerosing osteomyelitis

- Diffuse sclerosing osteomyelitis is an ill-defined, highly controversial, evolving area of dental medicine. This diagnosis encompasses a group of presentations that are characterized by pain, inflammation, and varying degrees of gnathic periosteal hyperplasia, sclerosis, and lucency.

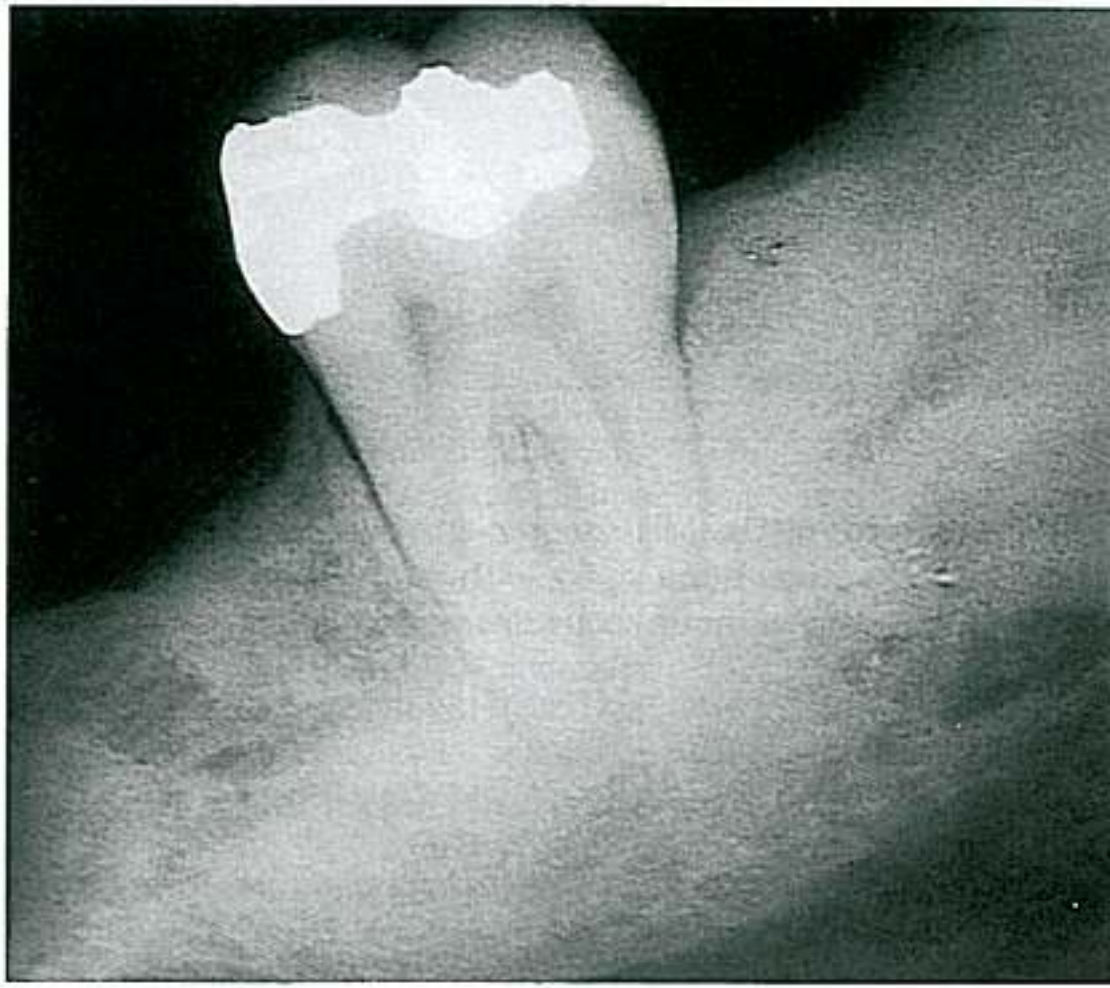

FIGURE 3-36

Diffuse chronic sclerosing osteomyelitis. A portion of a large diffuse area of radiopacity of the mandible that has indistinct boundaries indicative of increased bone density.

RADIOGRAPHICALLY.

- This process is diffuse, typically affecting a large part of the jaw and ill defined.
- **Early** lucent zones may appear in association with sclerotic masses.
- **In advanced stages**, sclerosis dominates the radiographic picture. Periosteal thickening may also be seen. Scintigraphy may be particularly useful in evaluating the extent of this condition.

HISTOPATHOLOGY

The microscopic changes of this condition are inflammatory, Fibrous replacement of marrow is noted

- A chronic inflammatory cell infiltrate and occasionally a neutrophilic infiltrate are also seen.
- Bony trabeculae exhibit irregular size and shape and may be lined by numerous osteoblasts.
- Focal osteoclastic activity is also present. The characteristic sclerotic masses are composed of dense bone, often exhibiting numerous reversal lines.

DIFFERENTIAL DIAGNOSIS

- Chronic sclerosing osteomyelitis shares many clinical, radiographic, and histological features with **florid osseous dysplasia.**
- The two should be separated, because the former is an **inf ammatory/infectious** process and the latter a bony **dysplastic** process. Treatment and prognosis are therefore dissimilar.
- Furthermore, f brid osseous dysplasia is usually **Asymptomatic** and appears as a f broosseous lesion lacking an inflammatory cell infiltrate.

Chronic osteomyelitis with proliferative periostitis (garré's osteomyelitis) (PERIOSTITIS OSSIFICANS)

Etiology

- known as Garré's osteomyelitis, is essentially a subtype of osteomyelitis that has a prominent **periosteal** inf ammatory reaction as an additional component.
- It most often results from a periapical abscess of a mandibular molar tooth or an infection associated with tooth extraction or partially erupted molars. It is most common in **children.**

A

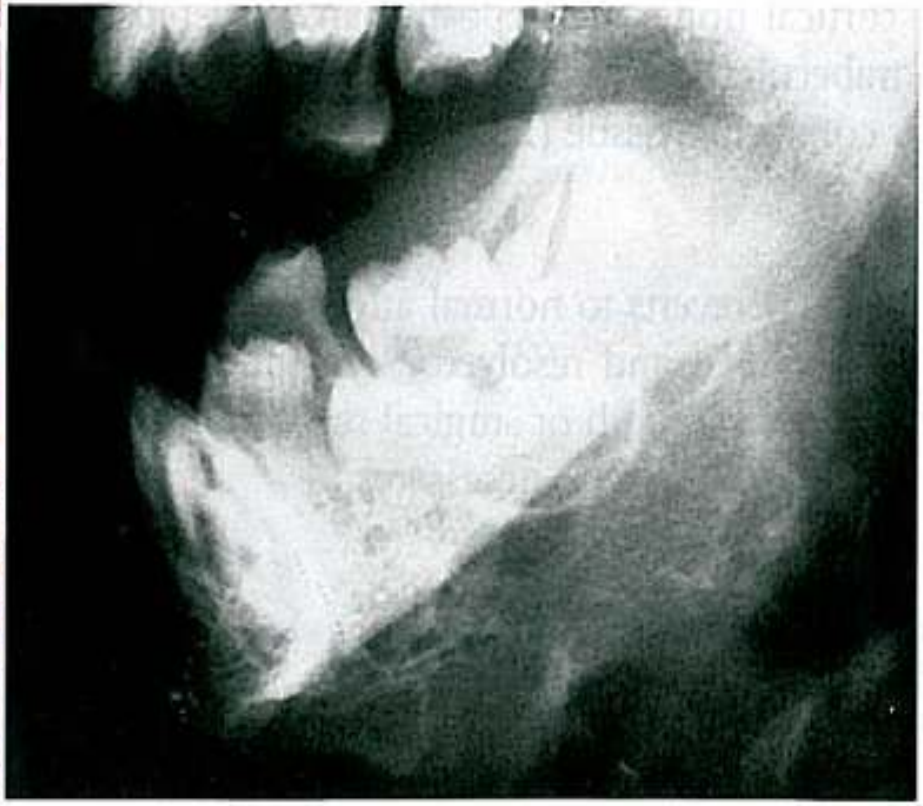

B

Garré osteomyelitis. A, Young patient with an enlargement of the left side of the face over the mandible. **B,** Lateral radiograph of the patient in **A** reveals a large mixed radiolucent and radiopaque area indicative of excess bone formation of the mandible. (Courtesy Dr. David G. Gardner.)

Chronic osteomyelitis with proliferative periostitis (garré's osteomyelitis)

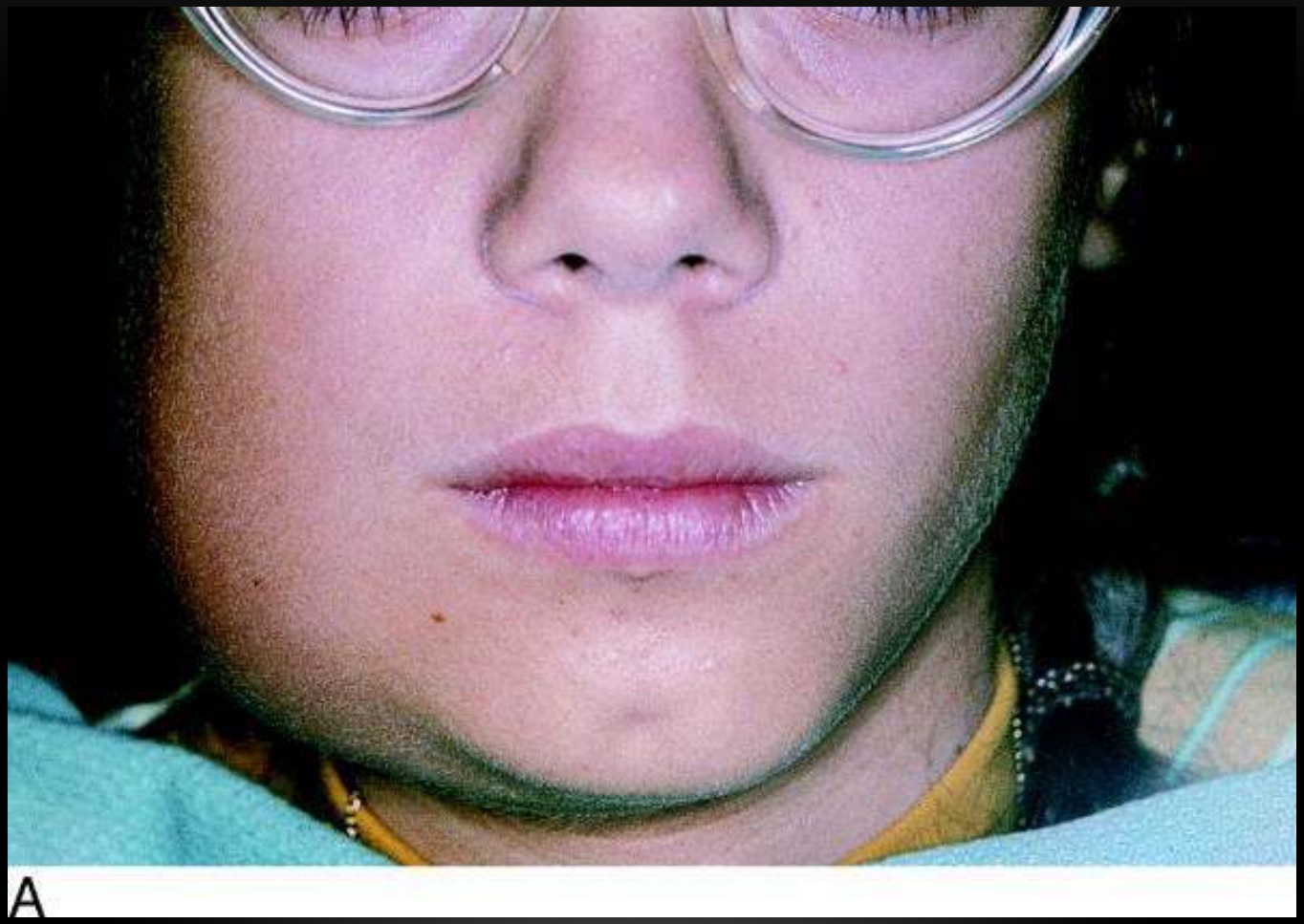

- Radiographically, the lesion appears centrally as a mottled, predominantly lucent lesion in a pattern consistent with that of chronic osteomyelitis.
- The feature that provides the distinctive difference is the periosteal reaction. This, best viewed on an **occlusal radiograph**, appears as an expanded cortex, often with concentric or parallel opaque layers. Trabeculae perpendicular to the onion skin layers may be apparent.

Chronic osteomyelitis with proliferative periostitis (garré's osteomyelitis) (PERIOSTITIS OSSIFICANS)

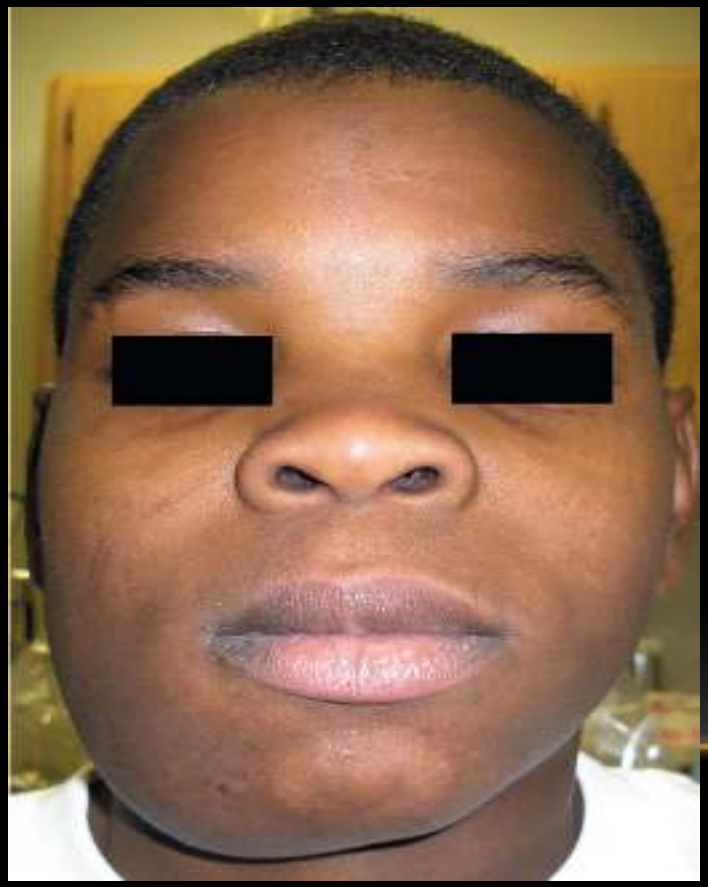

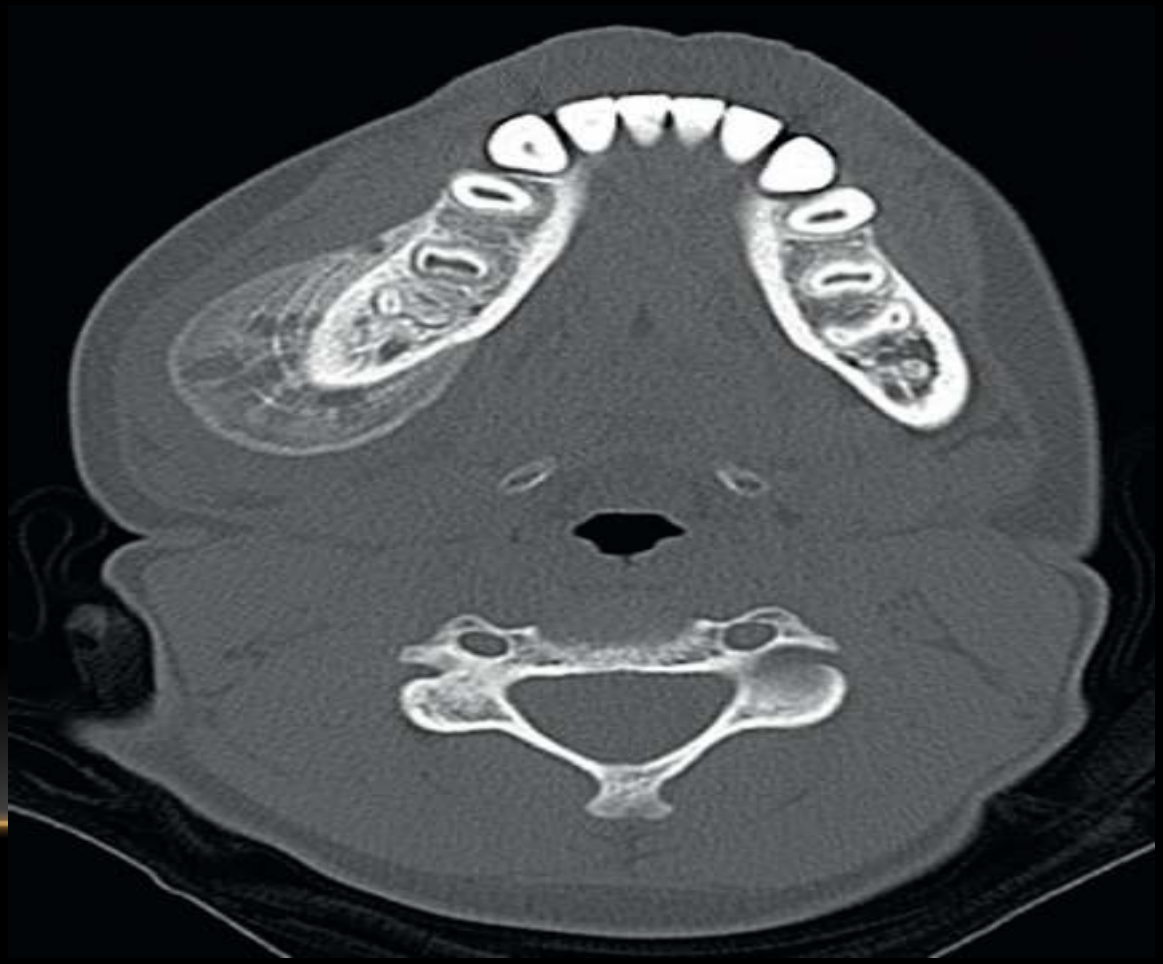

(PERIOSTITIS OSSIFICANS) HISTOPATHOLOGY

- Reactive new bone typifies the subperiosteal cortical response. Perpendicular orientation of new trabeculae to redundant cortical bone is best seen under low magnification.
- Osteoblasts dominate in this area, and both osteoblasts and osteoclasts are seen centrally. Marrow spaces contain fibrous tissue with scattered lymphocytes and plasma cells.
- Inflammatory cells are often surprisingly scant, making

FIGURE 3-38

Garré osteomyelitis. An occlusal radiograph of excess layers of bone on the buccal plate ("onion skin") opposite a partly erupted second molar.

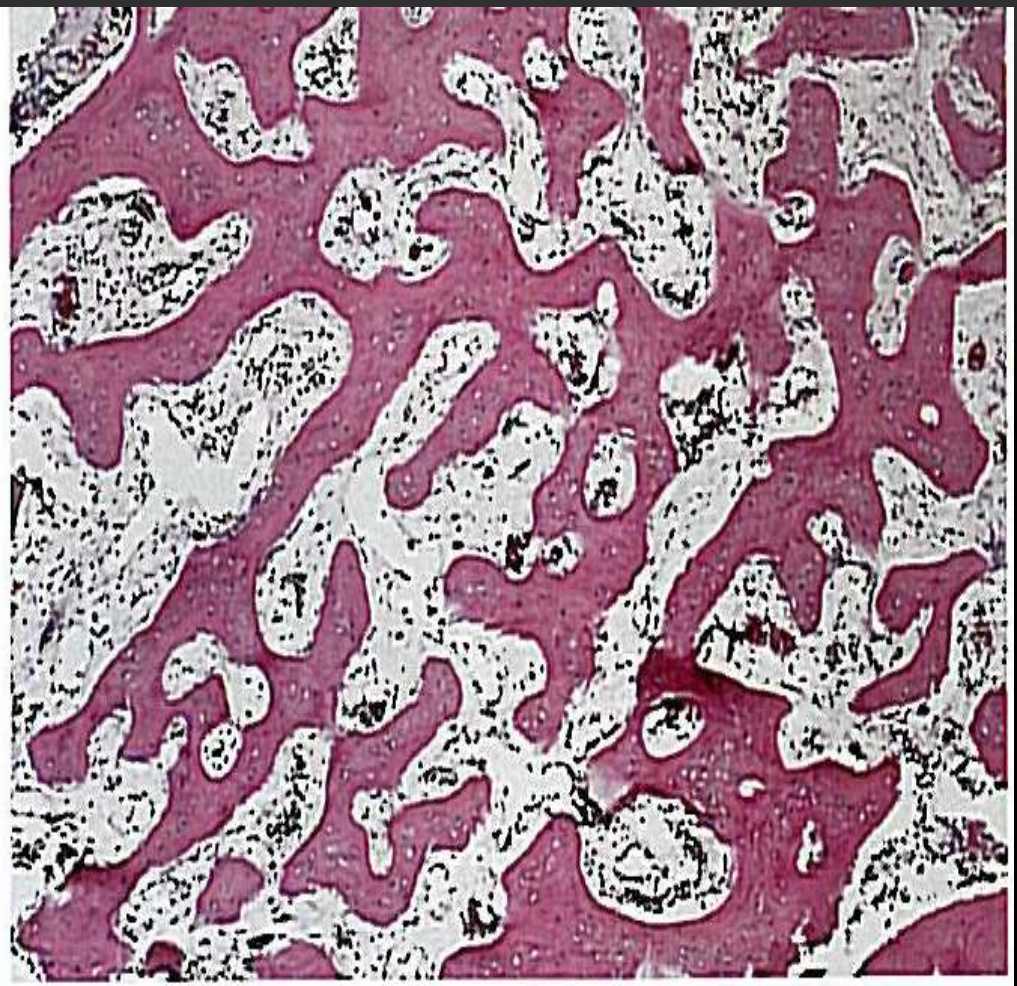

FIGURE 3-39

Garré osteomyelitis. Microscopic appearance of the periphery of excess porous bone layers with intervening cellular connective tissue and without cortex formation.

PROLIFERATIVE PERIOSTITIS.

INTERCONNECTING TRABECULAE OF NEW BONE FORMATION (TOP LEFT) EXTENDING FROM THE ORIGINAL CORTICAL SURFACE (DELINEATED BY ARROWS).

OSTEORADIONECROSIS

- Osteoradionecrosis is one of the most serious complications of radiation to the head and neck.
- Radiation of bone results in permanent damage:' to the osteocytes and microvasculature system. The altered bone **becomes hypoxic, hypovascular, and hypocellular.** Osteoradionecrosis is the result of non healing, dead bone; infection is not necessarily present.

fistula formation of the left submandibular area resulting from osteoradionecrosis of the mandibular body.

Osteoradionecrosis.

Multiple ill-defined areas of radiolucency and radiopacity of the mandibular body.

Alveolar osteitis
(dry socket; fibrinolytic alveolitis)

- Destruction of the initial clot prevents appropriate healing and causes clinical syndrome known as alveolar osteitis .
- Extensive investigations *have* shown that the clot is lost secondary to transformation of plasminogen to plasmin, with subsequent lysis of f brin and formation of kinins (f brinolytic alveolitis):

- These are potent pain mediators.
- Local trauma, estrogens, and bacterial pyrogens are known to stimulate fibrinolysins.
- This knowledge correlates well with the increased frequency of alveolar osteitis in association with inexperienced surgeons; Traumatic extractions.
- Oral contraceptive use. And presurgical infections.In addition, inadequate irrigation at surgery and the use of tobacco products have been related to the development of the problem.

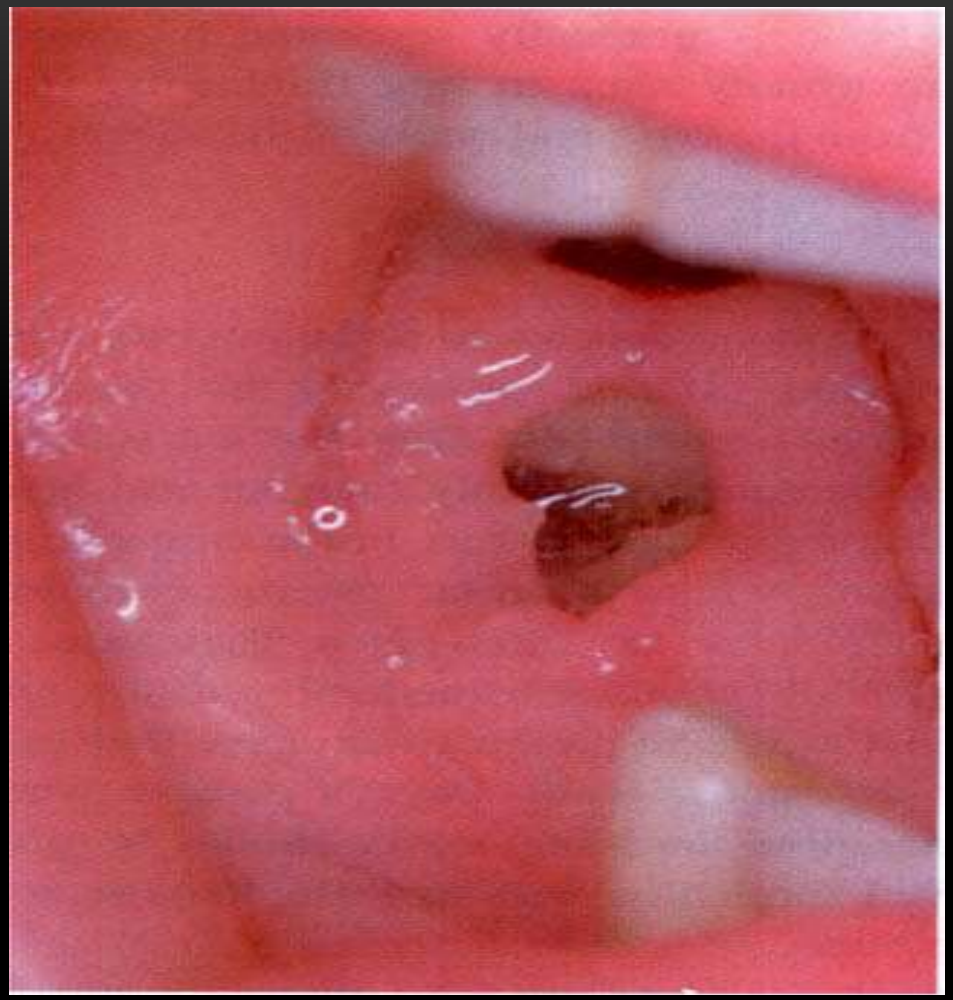

Dry socket.

socket is empty and the bony lamina dura is visible.

CLINICAL FEATURES

- The frequency of alveolar osteitis is higher in the mandible and the posterior areas. After oral contraceptive use is taken into account.
- They does not appear to be a significant sex predilection. The prevalence is between 1% and 3% of all extractions, but it increases to **25% to *30%*** for impacted mandibular third molars.
- The frequency appears to be decreased when impacted teeth are prophylactically removed rather than for therapeutic reasons after development of chronic

- The diagnosis is confirmed by probing of the socket, which reveals exposed and extremely sensitive bone. Typically, severe pain, foul odor, and (less frequently) swelling and lymphadenopathy develop 3 to 4 days after extraction of the tooth. The signs and symptoms may last from 10 to 40 days.

TREATMENT AND PROGNOSIS

- On evaluation of the patient complaining of post extraction pain, a **radiograph** should be taken of the affected area to rule out the possibility of a retained root tip or a foreign body.
- The socket is irrigated with warm saline, followed by thorough clinical inspection of the socket for any unexpected pathosis.
- **Curettage** of the socket **is not recommended,** because this typically increases the associated pain. Finally, the socket is packed with an obtundent and antiseptic dressing, such as iodoform gauze containing eugenol

- Use of antiseptic dressing, such as is controversial Typically, the dressing is changed every 24 hours for the f ṙst 3 days, then every 2 to 3 days until granulation tissue covers the exposed bone. Because it acts as a foreign material. The dressing should be discontinued as soon as the patient is out of pain.
- After that time the patient should be given a plastic syringe with instructions for home irrigation. The irrigation should be continued until the socket no longer collects any debris (usually 3 to 4 weeks).

- Many investigators have studied preventive measures for alveolar osteitis including systemic and topical antibiotics, cessation of smoking the day before and after surgery, copious surgical irrigation, and antifibrinolytic agents.
- Any topical antibiotic should not be in an ointment form because such use has resulted in chronic foreign body reactions